

PLATEAU IRIS – DIAGNOSIS AND TREATMENT

Stefan Cornel, Iliescu Daniela Adriana, Batras Mehdi, Timaru Cristina Mihaela, De Simone Algerino
Ophthalmology Department, „Dr. Carol Davila” Central Military Emergency University Hospital,
Bucharest, Romania

Correspondence to: Iliescu Daniela Adriana, MD,
„Dr. Carol Davila” Central Military Emergency University Hospital
134 Plevnei Street, District 1, Bucharest
Phone/Fax: +4021 313 71 89, E-mail: dparvu@ymail.com

Accepted: March 15, 2015

Abstract

Objectives: The objective of our study was to review the current knowledge on the diagnosis and treatment options of plateau iris configuration and syndrome.

Systematic review methodology: Relevant publications on plateau iris that were published until 2014.

Conclusions: Plateau iris syndrome is a form of primary angle closure glaucoma caused by a large or anteriorly positioned ciliary body that leads to mechanical obstruction of trabecular meshwork. This condition is most often found in younger patients. Plateau iris has been considered an abnormal anatomic variant of the iris that can be diagnosed on ultrasound biomicroscopy or optical coherence tomography of anterior segment. Patients with plateau iris syndrome can be recognized by the lack of response in angle opening after iridotomy. The treatment of choice in these cases is argon laser peripheral iridoplasty.

Keywords: plateau iris syndrome, primary angle closure glaucoma, trabecular meshwork, optical coherence tomography, iridotomy

Introduction

Plateau iris is one of the most frequent causes of primary angle-closure glaucoma in young patients. Most often, it is diagnosed in patients under 50 years of age that have narrow angle despite peripheral iridotomy properly done [1]. This form of angle closure is secondary to an anteriorly positioned ciliary body or of greater dimensions that can lead to mechanical obstruction of the trabecular meshwork [2].

Anatomical features and mechanism of angle-closure in plateau iris

A differentiation between “plateau iris configuration” and “plateau iris syndrome” must

be made. Plateau iris configuration refers to the situation in which the anterior chamber has a normal depth but the iris is plane. In this anatomical variation, the root of the iris is short and anteriorly inserted on the surface of the ciliary body. The forward positioned ciliary processes sustain the convexity of the peripheral iris, causing it to be in contact with the trabecular meshwork.

Plateau iris syndrome refers to the condition in which angle closure is still present confirmed by gonioscopy, despite a patent peripheral iridotomy that has removed a degree of pupillary block and without a shallow anterior chamber [3]. Patients with plateau iris syndrome usually associate an element of pupillary block so nevertheless iridotomy must be the first

choice of treatment. Plateau iris configuration is much more common than plateau iris syndrome. A differential diagnosis must be accounted for this syndrome when the intraocular pressure rises suddenly after adequate peripheral iridotomy.

Epidemiology

Patients who have plateau iris configuration and develop angle closure glaucoma are younger than those with primary angle-closure glaucoma through pupillary block (which account for 75% of cases). It is seen most commonly in women and the mean age at the first presentation for plateau iris syndrome is 40 years [4]. In a US review of patients with age under 60 years and recurrent angle closure symptoms, the prevalence of plateau iris syndrome in spite of initial iridotomy or iridectomy was 54% [5]. The prevalence seems to be increased in patients with a family history of plateau iris syndrome and the predisposition may be of autosomal dominant inheritance pattern [6]. In two studies, Kumar et al. used ultrasound biomicroscopy to find plateau iris configuration at least in two quadrants, in one third of the patients with primary angle closure glaucoma or those who were suspects of primary angle closure after laser iridotomy [7,8].

Diagnosis

History. Patients with plateau iris syndrome are often hyperopic, younger than those with primary pupillary block glaucoma, more commonly female and have a family history of angle closure glaucoma. The diagnosis may be done on routine examination or they may present with angle closure, spontaneously or after pupillary dilation.

Physical examination. Slit lamp examination shows normal anterior chamber depth and flat iris surface. Gonioscopy is the golden standard for the assessment of the angle opening. It must be done in a darkroom and with less bright slit beam. On gonioscopic examination, the angle is narrowed or closed. When indentation is performed, the double hump sign (known also as sigma sign) is seen. This sinuous configuration is determined by the ciliary processes that elevate

the iris root, the lens curvature that is taken over by the iris surface and the space between them [9]. These changes found in gonioscopic indentation cannot be observed in eyes with primary angle closure due to pupillary block [9]. More force is needed to open the angle on indentation in plateau iris than in pupillary block angle closure because the ciliary processes must be displaced. Besides gonioscopy, the measurement of intraocular pressure (IOP) by tonometry before and after pupillary dilation, after iridotomy has been performed, can indicate residual angle closure from plateau iris.

Plateau iris syndrome is defined by persistent occludable angle after patent iridotomy. The height to which the plateau iris rises determinates two subtypes of plateau iris syndrome and whether or not the angle will close completely.

- In complete plateau iris syndrome, the angle is closed to the upper trabecular meshwork or the Schwalbe line and IOP is increased due to aqueous outflow blocking.
- In incomplete plateau iris syndrome, the angle is partially closed; the upper trabecular meshwork remains opened, which allows drainage of aqueous humor so that the IOP will stay between normal values.

Patients with incomplete plateau iris syndrome and successful iridotomy can develop peripheral anterior synechiae and angle closure years after the treatment was initiated.

Ultrasound biomicroscopy (UBM). UBM is an image examination of the anterior segment that plays an important role in plateau iris assessment [8,11]. This method can be useful in:

- diagnosis and detection of anatomical changes found in plateau iris configuration: flat iris surface, anteriorly situated ciliary processes, absence of ciliary sulcus, anterior angulation of the peripheral iris in its insertion, steep, short or thick iris root, iridotrabecular contact and a normal central depth of the anterior chamber. This enables the explaining of the mechanism of plateau iris syndrome [7].
- illustration of multiple neuroepithelial cysts of the ciliary body (pseudo plateau iris) or other causes of narrow angle.

- confirmation of any pupillary block associated.

- performing a darkroom provocative test, which can provide information on whether the angle anatomically closes during scotopic conditions.

- evaluation of therapeutic outcome after laser iridotomy (the angle remains narrow in patients with plateau iris syndrome) or argon laser peripheral iridoplasty (effectively eliminates the appositional residual closure caused by the plateau iris syndrome).

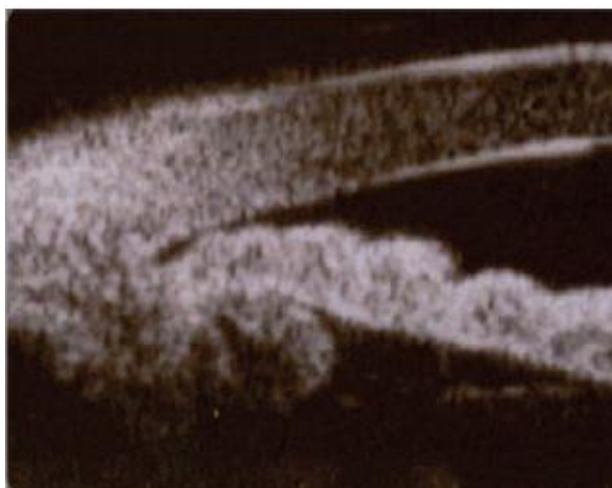


Fig. 1 Image of plateau iris configuration on UBM examination

Optical coherence tomography of anterior segment (OCT-SA). OCT-SA brings the same information as UBM but on a better resolution and has the advantage of a non-contact image investigation. Unlike the posterior segment, OCT-SA uses 1310 nm wavelength light source designed to have a low dispersion in the tissues and is able to provide a detailed visualization of the anterior chamber configuration [12,13].

Differential diagnosis

The differential diagnosis can be made with:

- *pseudo plateau iris* - comprises for other abnormalities of the ciliary body such as neuroepithelial cysts or iris cysts that cause the narrowing of the anterior chamber angle. This

term does not distinguish between different forms of cysts. The diagnosis can be easily made, as in case of one cyst the angle will close focal and be confirmed by imaging techniques [10,14].

- *ciliary body edema* - has a similar configuration as plateau iris. It is caused by sulfur containing drugs (topiramate), oral acetazolamide, thalidomide, idiopathic uveal effusion syndrome, increased choroidal venous pressure or systemic inflammatory disorders [15].

- *malign glaucoma* - is a subtype of secondary angle-closure glaucoma caused by anterior rotation of the ciliary body. It appears most commonly after filtering surgery and is due to the aqueous misdirection towards the posterior chamber and vitreous cavity.

- *ciliary body tumors.*
- *incomplete iridotomy.*
- *gas bubble after vitreoretinal eye surgery.*

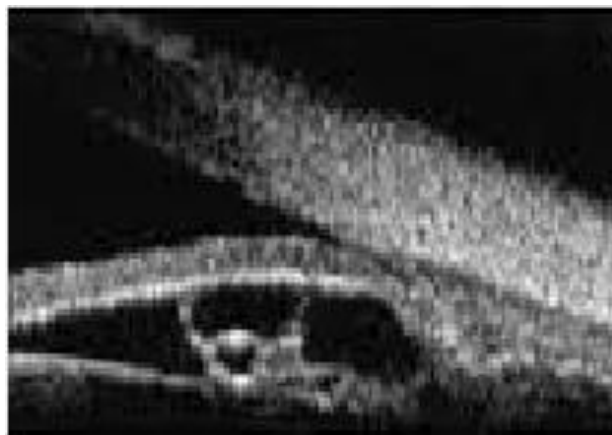


Fig. 2 Image of pseudo plateau iris (iris cyst) that narrows the angle

Medical treatment

The medical treatment consists of miotic drug administration: pilocarpine 1%, aceclidine 2% (muscarinic agents), carbachol 0.75% (muscarinic and nicotinic agent) and dapiprazole 0.5% (alpha-adrenergic agonist). These facilitate aqueous humor outflow through ciliary muscle contraction, distance the iris periphery from the trabecular meshwork, prevent synechia formation but do not totally remove

iridotrabecular contact. Miotic agents open the angle reducing the intraocular pressure by 20-25%. Adverse reactions can be local: ocular pain, conjunctival hyperemia, pupillary constriction, myopia, retinal detachment, or general: bronchospasm, headache, intestinal cramps [3]. This treatment is an option for acute and intermittent angle-closure and is mainly reserved for patients who do not consent to laser therapy [16]. Miotics can also be used for the prevention of the angle closure after laser iridotomy or argon laser peripheral iridoplasty [10].

Surgical treatment

Laser iridotomy (IT) - must always be the first choice of treatment. It excludes any associated pupillary block and helps to confirm plateau iris syndrome diagnosis. A patent iridotomy is a prevention procedure that reduces the risk of angle closure. Even after iridotomy has opened the angle in a satisfactorily manner, periodic gonioscopy is still essential because the angle may narrow with age or patients may have incomplete plateau iris syndrome. Patients with plateau iris configuration must not be assumed to be cured and plateau iris syndrome may develop years later [16].

IT procedure - can be done with Nd:YAG or argon laser. Lenses that can be used are Abraham (+66D), Wise (+103D) or CGI Lasag. Iridotomy is usually done in the superior quadrant of the iris or in a iris crypt. After the iridotomy has been made, it should be horizontally enlarged so that it remains permeable in case of oedema, proliferation of pigment epithelial or pupil dilation.

Nd:YAG laser iridotomy - is done by using the following parameters: power 1-6 mJ, spot size 50-70 μm and 1-3 pulses per burst. If the iris is thick and/ or dark, a prior treatment with argon laser can be considered.

Argon laser iridotomy - it is generally done when Nd:YAG laser is not available. Parameters are adjusted according to iris thickness and color.

IT complications - hyphema, visual disturbances (halo, glare), epithelial or endothelial burns, transient elevations of IOP,

emergence of synechia or closure of iridotomy site [3].

Argon laser peripheral iridoplasty (ALPI) - is the definitive treatment and the procedure of choice that opens the angle in case of plateau iris syndrome. It is indicated when laser iridotomy is not efficient. ALPI is highly useful in the reduction of appositional closure of the iris periphery to the trabecular meshwork and in opening the angle. This procedure reduces the risk of later synechial formation [10]. In rare cases, ALPI can be repeated. Studies that analyzed the iris after ALPI treatment by means of spectral domain optical coherence tomography showed that the angle opened where laser burns were applied on the surface of the iris but remained closed at untreated areas. Also there was a significant cross-sectional thinning of the iris at areas treated with laser. The finding suggests that contraction of iris stroma and thinning of the tissue done by ALPI will open the angle [17]. This indicates that ALPI technique must be done as far peripheral as possible [11]. Lenses that can be used are Abraham (+66D), Wise (+103D) or CGI Lasag. For photocoagulation, diode laser (810nm) and frequency laser Nd:YAG laser (532 nm) can also be used.

Argon laser parameters - spot size 200-500 μm , exposure 0.3-0.6 sec, power 200-400 mW. Laser spots must be directed to the peripheral part of the iris. The optimal effect is the contraction of iris periphery that is visible and flattening of iris curvature [3]. Possible complications of the procedure are iritis, burns of the corneal endothelium, atrophy of the iris, IOP elevation, and synechia. Steroid and non-steroid anti-inflammatory medication can be administered in the post-laser management [18,19].

Alternative treatment procedures: are reserved to patients who have persistent angle closure despite laser iridotomy and argon peripheral iridoplasty. This can include the following treatment choices: anterior chamber paracentesis (for angle closure glaucoma cases), trabeculectomy (difficult because of possible anterior protrusion of ciliary processes through scleral ostium), goniosynechialysis, lens extraction, shunt implantation surgery or endophotocoagulation of ciliary processes [3].

Evolution and prognosis

Patients with narrow angle and plateau iris configuration can develop acute or chronic angle closure. It is very important for these cases to have periodic follow-up screening for the assessment of an eventual angle narrowing. These patients must be individually evaluated and the risk between extensive treatment and a possible closure of the angle must be put in balance. The prognosis is good in general. Appropriate information of the patient about a chronic condition that was initially treated with success is essential [3,10].

Acknowledgment: This paper is partly supported by the Sectorial Operational Programme Human Resources Development (SOPHRD), financed by the European Social Fund and the Romanian Government under the contract number POSDRU 141531.

References

1. Ritch R. Plateau iris is caused by abnormally positioned ciliary processes. *J Glaucoma*. 1992; 1:23.
2. Diniz Filho A, Cronemberger S, Mérula RV, Calixto N. Plateau iris. *Arq Bras Oftalmol*. 2008; 71(5):752-8.
3. Terminology and Guidelines for Glaucoma. 2014, s.l.: European Glaucoma Society, 43-46, 105-110, 112-113, 161-167.
4. Wand M, Grant WM, Simmons RJ, Hutchinson BT. Plateau iris syndrome. *Trans Sect Ophthalmol Am Acad Ophthalmol Otolaryngol*. 1977; 83(1):122-30.
5. Stieger R, Kniestedt C, Sutter F, Bachmann LM, Stuermer J. Prevalence of plateau iris syndrome in young patients with recurrent angle closure. s.l.: *Clin Experiment Ophthalmol*. 2007; 35(5):409-13.
6. Etter JR, Affel EL, Rhee DJ. High prevalence of plateau iris configuration in family members of patients with plateau iris syndrome. *J Glaucoma*. 2006; 15(5):394-8.
7. Kumar RS, Baskaran M, Chew PT, Friedman DS, Handa S, Lavanya R, Sakata LM, Wong HT, Aung T. Prevalence of plateau iris in primary angle closure suspects an ultrasound biomicroscopy study. *Ophthalmology*. 2008; 115(3):430-4.
8. Kumar G, Bali SJ, Panda A, Sobti A, Dada T. Prevalence of plateau iris configuration in primary angle closure glaucoma using ultrasound biomicroscopy in the Indian population. *Indian J Ophthalmol*. 2012; 60(3):175-8.
9. Kiuchi Y, Kanamoto T, Nakamura T. Double hump sign in indentation gonioscopy is correlated with presence of plateau iris configuration regardless of patent iridotomy. *J Glaucoma*. 2009; 18(2):161-4.
10. Glaucoma, American Academy of Ophthalmology. 2009-2010, s.l.: Elsevier Masson, 123-134.
11. Parc C, Laloum J, Bergès O. Comparison of optical coherence tomography and ultrasound biomicroscopy for detection of plateau iris. *J Fr Ophtalmol*. 2010; 33(4):266.
12. Kalev-Landoy M, Day AC, Cordeiro MF, Migdal C. Optical coherence tomography in anterior segment imaging. *Acta Ophthalmol Scand*. 2007; 85(4):427-30.
13. Nema HV, Nema N. *Diagnostic Procedures in Ophthalmology*. 2014, s.l.: Jaypee Brothers Medical Publishers, 263-266.
14. Choplin NT, Lundy DC. *Atlas of Gaucoma*. 2007, s.l.: Thomson, 149-160.
15. Quigley HA, Friedman DS, Congdon NG. Possible mechanisms of primary angle-closure and malignant glaucoma. *J Glaucoma*. 2003; 12(2):167-80.
16. Ng WT, Morgan W. Mechanisms and treatment of primary angle closure: a review. *Clin Experiment Ophthalmol*. 2012; 40(4):e218-28.
17. Liu J, Lamba T, Belyea D. Peripheral laser iridoplasty opens angle in plateau iris by thinning the cross-sectional tissues. *Clinical Ophthalmology*. 2013; (7):1895-1897.
18. Ritch R, Tham CC, Lam DS. Argon laser peripheral iridoplasty (ALPI): an update. *Surv Ophthalmol*. 2007; 52(3):279-88.
19. Ouazzani BT, Berkani M, Ecoffet M, Lachkar Y. Argon laser iridoplasty in the treatment of angle closure glaucoma with plateau iris syndrome. *J Fr Ophtalmol*. 2006; 29(6):625-8.