

AGE-RELATED MACULAR DEGENERATION

Andreea Gheorghe, Labib Mahdi, Ovidiu Musat
Ophthalmology Department, "Dr. Carol Davila" Central Military
Emergency University Hospital, Bucharest, Romania

Correspondence to: Andreea Gheorghe, MD
Ophthalmology Department, "Dr. Carol Davila" Central Military Emergency University Hospital, Bucharest
134 Plevnei Street, District 1, Bucharest, Romania
Phone/ Fax: +4021 313 71 89, E-mail:gheorghe.andreea88@yahoo.com

Accepted: April 8, 2015

Abstract

Objectives: The objective of our study was to review the current knowledge on Age-Related Macular Degeneration, including pathogenesis, ocular manifestations, diagnosis and ancillary testing.

Systematic review methodology: Relevant publications on Age-Related Macular Degeneration that were published until 2014.

Conclusions: Age-related macular degeneration (AMD) is a common macular disease affecting elderly people in the Western world. It is characterized by the appearance of drusen in the macula, accompanied by choroidal neovascularization (CNV) or geographic atrophy.

Keywords: choroidal neovascularization, geographic atrophy, age related macular degeneration

Introduction

Age-related macular degeneration is a common, chronic, progressive degenerative disorder of the macula that affects older individuals and features loss of central vision as a result of abnormalities in the photoreceptor/retinal pigment epithelium/Bruch's membrane/choroidal complex often result in geographic atrophy and/or neovascularization. Advanced AMD can be classified broadly into two types: dry and wet. Although dry AMD accounts for the majority of all diagnosed cases, wet AMD is responsible for the majority of the severe vision loss and it usually occurs over weeks to months. Although neovascularization has been the most common cause of severe vision loss, geographic atrophy, the most advanced form of dry AMD, can cause a significant loss of vision as well.

Epidemiology

Globally, AMD ranks third as a cause of blindness after cataract and glaucoma. Most of the affected individuals live in developed countries. In general, advanced AMD is rare before the age of 55, and more common in persons of 75 years and older. The prevalence of neovascular AMD and geographic atrophy appears to vary in different ethnic and racial groups throughout the world. The prevalence of advanced AMD increases with each decade after the age of 50 with the highest prevalence occurring after the age of 80.

Risk factors

Risk factors for AMD may be broadly classified into personal or environmental factors (e.g., smoking, sunlight exposure, and nutritional

factors including micronutrients, dietary fish intake, and alcohol consumption).

Personal factors may be further subdivided into sociodemographic (e.g., age, sex, race/ethnicity, heredity, and socioeconomic status), ocular (e.g. iris color, macular pigment optical density, cataract and its surgery, refractive error, and cup/ disc ratio), and systemic factors (e.g., cardiovascular disease and its risk factors, reproductive and related factors, dermal elastotic degeneration, and antioxidant enzymes).

Risk factors for progression to choroidal neovascularization. Presence of five or more drusen, hyperpigmentation, systemic hypertension, one or more large drusen (> 63 µm in greatest linear dimension), white race, and smoking.

Pathogenesis

The cause of AMD is currently being elucidated through the molecular dissection of histopathologic specimens and genetic linkage analyses by using different populations. Early in the disease process, lipids are deposited in Bruch's membrane, possibly from failure of the RPE to process cellular debris associated with outer segment turnover. Only later in the disease process are drusen visible. The appearance of drusen is the earliest visible clinical sign of AMD.

Analysis of drusen reveal that they contain lipid, amyloid, complement factors, and additional cellular components [1,2].

The appearance of drusen is preceded by or concomitant with the thickening of the Bruch's membrane collagenous layers, degeneration of elastin and collagen within Bruch's membrane with calcification of the membrane, increased levels of advanced glycation end products, and accumulation of lipids as well as exogenous proteins [3]. These changes may serve as a hydrophobic barrier to impede the passage of fluid and nutrients between the choroid and outer retina resulting in relative ischemia. Subsequent ingrowth of neovascularization from the choriocapillaris may then occur through fractures in Bruch's membrane [4].

Ocular manifestation

Dry Age-Related Macular Degeneration

Drusen are one of the earliest signs in AMD. Clinically, typical drusen appear as focal, whitish

yellow excrescences deep to the retina. Typical drusen deposits are located beneath the retinal pigment epithelium and Bruch's membrane and vary widely in number, shape size, and distribution. Most drusen are 20-100 µm and are characterized as hard or soft.

Hard drusen, which appear as round, discrete yellow-white spots are commonly identified in many populations. They are not age-related and do not carry an increased risk for the development of neovascularization [5,6]. In contrast, soft drusen are ill defined, with non-discrete borders, measuring 63 µm or greater. Different studies and trials have indicated that large, soft, confluent drusen are age-related and associated with a higher risk for the development of advanced AMD with neovascularization [6,7].

Geographic atrophy is easily recognized clinically, as it appears as a well-demarcated area of decreased retinal thickness, compared to the surrounding retina, with a relative change in color that allows an increased visualization of the underlying choroidal vessels. Pigmentary alteration may be present, either hypopigmentation or hyperpigmentation, surrounding the macular atrophy.

If the foveal center is spared, good visual acuity may be preserved, although reading vision may remain poor because of a constricted central visual field [8].

Wet (neovascular) Age-Related Macular Degeneration

Wet AMD is characterized by the presence of neovascularization within the macula.

Choroidal neovascularization (CNV) is an ingrowth of new vessels from the choriocapillaris through a break in the outer aspect of Bruch's membrane into the sub-pigment epithelial space.

The clinical manifestations of neovascular AMD can include the following: subretinal fluid, intraretinal fluid, retinal, subretinal, or sub-RPE hemorrhage, lipid exudates, gray or yellow-green discoloration or plaque-like membrane, RPE detachment, RPE tear.

In the end-stage of the disease, the neovascularization results in a fibrovascular or atrophic macular scar (*disciform scar*), and subsequent permanent damage to the central vision [9-11].

Pigment epithelial detachment - a retinal pigment detachment (PED) may be caused by serous fluid, fibrovascular tissue, hemorrhage, or the coalescence of drusen beneath the RPE. Serous PED manifests as a dome shaped detachment of the RPE, exhibiting bright, diffuse hyperfluorescence with progressive pooling in a fixed space [12]. Hemorrhagic PED manifests as a dark elevation of the RPE due to underlying blood, showing blocked fluorescence throughout all phases of angiography [13].

Diagnosis and ancillary testing

Clinical examination is usually sufficient to establish a diagnosis of AMD, although subtle macular abnormalities are best detected with the help of ancillary tests such as fundus autofluorescence, optical coherence tomography, fluorescein angiography, and indocyanine green angiography.

Optical coherence tomography may be a useful ancillary test in any stage of AMD. In patients with dry AMD, the high definition B-scans are useful to assess the ultra-structure of drusen and to examine adjacent retinal layers that can be compromised by the disease process.

The progression of early AMD to severe forms, such as geographic atrophy, can be monitored by OCT. The high definition B-scans can be used to identify some of the wet AMD features, such as the presence of intraretinal or subretinal fluid, presence of retinal PEDs, which can be classified in serous, fibrovascular, and hemorrhagic PEDs.

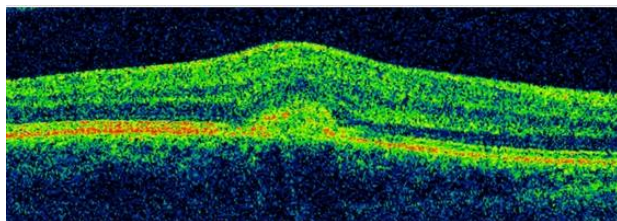


Fig. 1 Pigment epithelial detachment

Fundus autofluorescence represents an imaging modality capable of reflecting the morphological changes associated with the metabolism of lipofuscin. Areas of geographic atrophy exhibit very low to extinguished

fluorescence signals (dark) due to loss of RPE and lipofuscin, which leads to a region with a high contrast transition between the area of atrophy and perilesional retina.

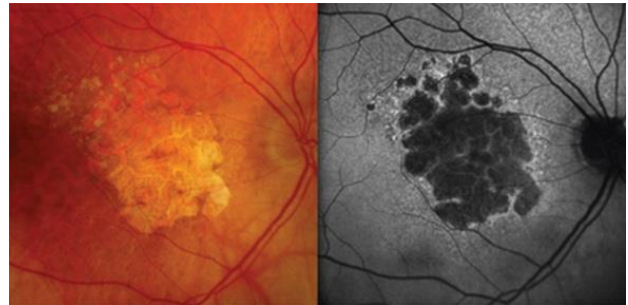


Fig. 2 Fundus autofluorescence - geographic atrophy

Fluorescein angiography is usually performed to confirm the presence of neovascularization and identifies the characteristics of the lesion, including the location and composition of the neovascularization. Based on the angiographic patterns of fluorescence, the neovascular lesion may be categorized as either classic or occult. Classic CNV is characterized by bright, uniform, early hyperfluorescence exhibiting leakage in the late phase and obscuration of the lesion's boundaries.

Occult CNV is angiographically recognized by one of two patterns: fibrovascular PED or late leakage from an undetermined source. Fibrovascular PED is characterized by an area of irregular elevation of the RPE (which is neither as bright nor as discrete as in classic CNV), often with stippled hyperfluorescence present in the midphase of the angiogram and leakage or staining by the late phase [13].

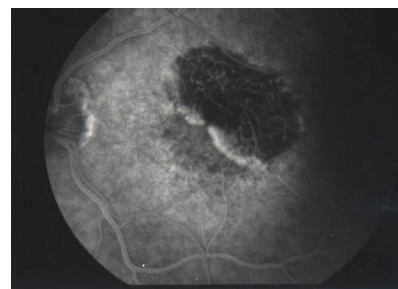


Fig. 3 Classic CNV

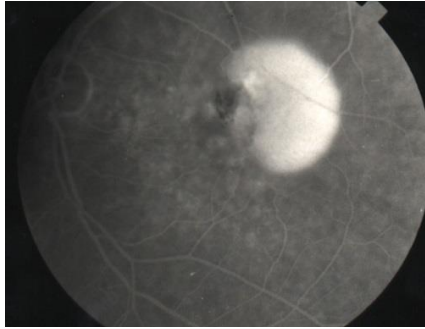


Fig. 4 Occult CNV

Indocyanine green angiography was used to diagnose and guide treatment in patients with AMD. The dye's characteristics enabled this mode of angiography to delineate the choroidal circulation better than fluorescein angiography.

In patients with dry AMD, indocyanine green angiography it might help identify plaques representative of asymptomatic choroidal neovascularization, which may represent areas of occult CNV, or watershed zones that may be predictive of future exudative transformation.

Indocyanine green angiography is of a particular value in the following circumstances:

- Occult or poorly defined CNV
- CNV associated with overlying hemorrhage fluid or exudate
- Distinguishing serous from vascularized portions of a fibrovascular PED [14]

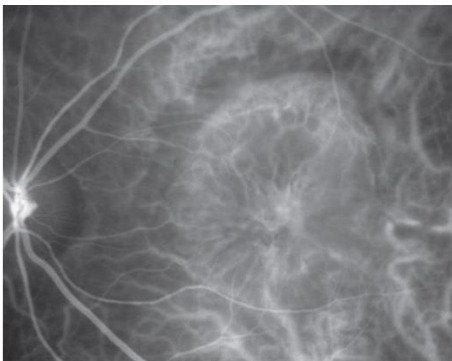


Fig. 5 Classic choroidal neovascularization. Early phase indocyanine green angiogram

References

1. Mullins RF, Russell SR, Anderson DH et al. Drusen associated with aging and age-related macular degeneration contain proteins common to extracellular deposits associated with atherosclerosis, elastosis, amyloidosis, and dense-deposit disease. *Faseb J.* 2000; 14: 835–46.
2. Johnson LV, Leitner WP, Staples MK et al. Complement activation and inflammatory processes in Drusen formation and age related macular degeneration. *Exp Eye Res.* 2001; 73:887–96.
3. Green WR, McDonnell PJ, Yeo JH. Pathologic features of senile macular degeneration. *Ophthalmology.* 1985; 92:615–27.
4. Pauleikhoff D, Harper CA, Marshall J et al. Aging changes in Bruch's membrane. A histochemical and morphologic study. *Ophthalmology.* 1990; 97:171–8.
5. Martin D, Maguire M, Fine S et al. Ranibizumab and bevacizumab for neovascular age-related macular degeneration (AMD). *N Engl J Med.* 2011; 364:1897–908.
6. Klein R, Klein BE, Knudtson MD et al. Fifteen-year cumulative incidence of age-related macular degeneration: the Beaver Dam Eye Study. *Ophthalmology.* 2007; 114:253–62.
7. Cohen SY, Dubois L, Tadayoni R et al. Prevalence of reticular pseudodrusen in age-related macular degeneration with newly diagnosed choroidal neovascularisation. *Br J Ophthalmol.* 2007; 91:354–9.
8. Schmitz-Valckenberg S, Steinberg JS, Fleckenstein M et al. Combined confocal scanning laser ophthalmoscopy and spectral-domain optical coherence tomography imaging of reticular drusen associated with age-related macular degeneration. *Ophthalmology.* 2010; 117:1169–76.
9. Zayit-Soudry S, Moroz I, Loewenstein A. Retinal pigment epithelial detachment. *Surv Ophthalmol.* 2007; 52:227–43.
10. Gregori G, Wang F, Rosenfeld PJ et al. Spectral domain optical coherence tomography imaging of drusen in nonexudative age-related macular degeneration. *Ophthalmology.* 2011; 118:1373–9.
11. Garcia Filho CA, Rosenfeld PJ, Yehoshua Z et al. Spectral-domain optical coherence tomography imaging of age-related macular degeneration. *US Ophthalmic Review.* 2011; 5:98–103.
12. Holz FG, Bellman C, Staudt S et al. Fundus autofluorescence and development of geographic atrophy in age-related macular degeneration. *Invest Ophthalmol Vis Sci.* 2001; 42:1051–6.
13. Yanoff M. *Ophthalmology.* Fourth Edition.
14. Kanski. *Clinical Ophthalmology: a systemic approach.*