

Partial results after treatment of diabetic macular edema with Bevacizumab

Giurgică Marius, Chiseliță Dorin, Dimofte Doina
Gr. T. Popa University of Medicine and Pharmacy, Iasi, Romania
Faculty of Medicine Discipline of Ophthalmology, "Sf. Spiridon" University Hospital, Iasi, Romania
"Oftaprof" Ophthalmology Clinic, Iasi, Romania

Correspondence to: Marius Giurgică
Ophthalmology Department, "Sf. Spiridon" University Hospital,
1 Independentei Street, zip code 700111, Iasi, Romania
Phone/fax: +40232 217 781, Mobile phone: +40729 85 39 44, E-mail: giurgicamarius21@yahoo.com

Accepted: October 25, 2015

Abstract

Purpose: To present the morphological and functional results after treating diabetic macular edema with Bevacizumab.

Patient and method: It is a prospective trial which includes 15 patients with diabetic macular edema (proved by OCT and fluorescein angiography examination). The inclusion criteria are: central retinal thickness over 250 μm , visual acuity of the studied eye between 0.1 and 0.5, absence of a previous treatment. We excluded patients with macular edema caused by other etiology or with any other macular disease. Every patient was treated with 3 intravitreal injections with Bevacizumab at every 6 weeks; we analyzed the results after 4 months.

Results: The mean visual acuity improved from 0.33 ± 0.06 at baseline to 0.49 ± 0.13 at 4 months (or from 31 ± 3.9 ETDRS letters to 39 ± 5.67 letters). The central retinal thickness decreased from $457 \pm 174 \mu\text{m}$ to $338 \pm 139 \mu\text{m}$. There was also an improvement of retinal sensibility on the microperimetry map.

Conclusions: The treatment of diabetic macular edema produced an increase of visual acuity and a decrease of macular thickness after the first 3 injections with Avastin, but it is necessary to monitor the patients to detect the rebound of the edema and to initiate retreatment.

Key words: diabetic macular edema, macular thickness, Bevacizumab

Introduction

Diabetic macular edema is a form of diabetic retinopathy which involves the central part of the retina and it is the main cause of vision loss in active population in developed countries [1]. Its incidence is highly correlated with the duration of diabetes and with poor glycaemic control [2].

Chronic hyperglycemia produces some biochemical processes, including: increasing the capillary permeability, activation of cytokines, alteration of blood flow, and the consequence is the lesion of the blood-retinal barrier and the accumulation of intraretinal or subretinal fluid. Chronic hypoxia stimulates the production of VEGF (vascular endothelial growth factor) which stimulates the inflammation and the angiogenesis [3].

Some clinical trials have proved the role of anti-VEGF agents in the treatment of this pathology. The purpose of the study is to show the morphological and functional results after treatment of diabetic macular edema with Bevacizumab.

Patients and method

It is a prospective study and the participants are patients with diabetes (type I or II) and diabetic macular edema (proved by OCT-SD exam).

The inclusion criteria are: age over 18 years, central retinal thickness over 250 μm , visual acuity of the studied eye among 0.1 and 0.5 (or among 5 or 40 ETDRS letters), visual acuity of the other eye over 0.1, absence of any form of previous treatment for macular edema (laser, corticosteroids, anti VEGF-agents).

The exclusion criteria are: macular ischemia (demonstrated by fluorescein angiography examination), presence of macular edema caused by other etiology (venous occlusion, posterior uveitis, etc.), presence of any other macular pathology which may interfere with the final results (epiretinal membrane, vitreo-macular traction syndrome etc.), proliferative retinopathy which may need photocoagulation, inability to come to regular visits.

All the patients signed an informed consent at the beginning of the study and a complete ophthalmological examination was performed, including OCT-SD exam and fluorescein angiography for detecting the type of leakage and the presence of macular ischemia. Microperimetry was also performed, 4-2 strategy, on an area of 9^o around the point of fixation.

The protocol of the study involves treatment with 3 intravitreal injections (every 6 weeks) with Bevacizumab, and then reinjection according to changes of visual acuity and macular thickness. A complete ophthalmological examination (including OCT and angiography exam) is made after 4, 6, 9 and 12 months after the baseline moment.

Results

1. 15 patients were treated with 3 intravitreal injections (the study is ongoing). The mean age

of the patients is $60.6 \pm 3,4$ years. The duration of diabetes is 17.6 ± 3 years, and the value of glycosylated hemoglobin A1c is 7.45 ± 0.5 %.

2. At 4 months, the mean Snellen visual acuity changed from 0.33 ± 0.06 at baseline to 0.49 ± 0.13 [Fig. 1], difference which is statistical significant ($p=0.02$).

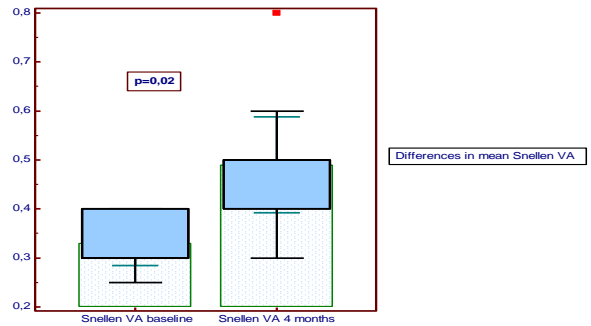


Fig. 1. Mean Snellen visual acuity at baseline vs 4 months

The ETDRS visual acuity changed from $31 \pm 3,9$ letters at baseline to $39 \pm 5,67$ letters at 4 months [Fig. 2], difference which is highly statistical significant ($p = 0.001$). Only one patient gained more than 15 letters.

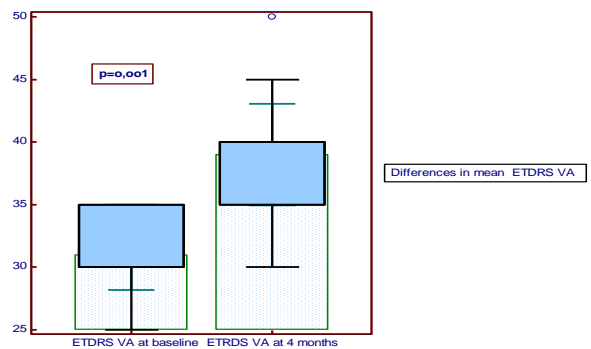


Fig. 2. Mean ETDRS visual acuity at baseline vs 4 months

There was no difference between the phakic and pseudophakic eyes regarding the changes of visual acuity.

3. The mean central retinal thickness changed from 457 ± 174 μm at baseline to 338 ± 139 μm at 4 months [Fig. 3], difference which

did not reached the statistical significance level ($p=0,1$).

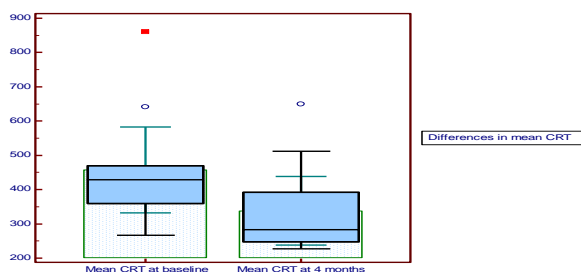


Fig. 3 Mean CRT (central retinal thickness) at baseline vs 4 months

Although there was a weak positive correlation ($r = 0.1$) between the decrease of macular thickness and the increase of visual acuity, there was not a direct relation between those 2 parameters; the correlation was not statistical significant.

4. When we analyzed the degree of macular thickness decrease according to the OCT aspect at baseline, the best response to treatment was for the cases with intraretinal fluid compared to those with subretinal fluid or cystic edema.

5. There was also an improvement of retinal sensibility on the microperimetry map (from a mean of 294 dB at baseline to 367 dB at 4 months), which correlates positively with the decrease of macular thickness.

6. There was not any local or systemic severe adverse effects (endophthalmitis, tear of the retinal pigment epithelium, stroke, myocardial infarction).

Discussion

The treatment of diabetic macular edema with Bevacizumab produced an increase of visual acuity with 0.15 on the Snellen chart (or 8 letters on the ETDRS chart) after the first 3 injections, but only one patient gained more than 15 letters. These facts (although there are initial results) seem to justify the treatment of this affection with Bevacizumab. In a similar study, Lam (4) reported almost the same results after 6 months of follow-up (a change of visual acuity from 0.4 to 0.5 after 3 intravitreal injections with Avastin).

There was a mean change of central retinal thickness of 119 μm . Although it did not reach the level of statistical significance, there was a weak correlation with the increase of visual acuity. There is not a relationship between the macular thickness and the visual acuity, because we analyze these 2 parameters we have to take into consideration several factors: the duration of the edema, the degree of structural damage induced by the edema, the quality of the macular perfusion.

Otani (5) showed a strong correlation ($r=0.6$) between the visual acuity and the degree of damage of the inner/outer segment junction of the photoreceptors at eyes with diabetic macular edema and a negative correlation ($r= - 0.1$) between the visual acuity and the central retinal thickness.

The response to treatment was different according to the OCT aspect at baseline. The best response was for the patients who had diffuse intraretinal edema and the worst was for those who had subretinal fluid or cystic edema. Also the decrease of the macular thickness was lower at eyes with very important edema at baseline (over 600 μm).

A clinical trial which investigated the relationship between the aspect of the edema on the OCT exam and the visual acuity proved a weak correlation ($r=0.2$) between the macular volume and the visual acuity. There was also a negative correlation between the thickness of the outer segment of the photoreceptors and the degree of vision impairment (7).

The microperimetry changes suggest an improvement of retinal sensibility after the decrease of retinal thickness. We observed this fact on the topographical analysis of the OCT images, except the location where the hard exudates persisted after the initial treatment. This idea will have to be confirmed by the future studies because there is also the possibility of a learning curve (similar to standard perimetry).

Conclusions

Although the treatment of diabetic macular edema produced an increase of visual acuity and a decrease of macular thickness after the first 3 injections with Avastin, taking into consideration the chronic character of the disease, it is necessary to monitor the patients (by OCT and

fluorescein angiography) to detect the rebound of the edema and to initiate an individualized retreatment.

Acknowledgment

Title of the project : "Program de excelență în cercetare doctorală și postdoctorală multidisciplinară în bolile cronice"

Number of identification : POSDRU/159/1.5/S/133377

Beneficiary: University of Medicine and Pharmacy "Grigore T. Popa" Iasi

References

1. Deshpande AD, Harris-Hayes M, Schoutman M. "Epidemiology of diabetes and diabetes-related complications", *Phys Ther* 2008; 88: 1254-1264
2. Bhagat N, Grigorian RA, Tutela A. "Diabetic macular edema: pathogenesis and treatment" *Surv Ophthalmol* 2009; 54: 1-32.
3. Murata T, Ishibashi T, Khalil A. "Vascular endothelial growth factor plays a role in hyperpermeability of diabetic retinal vessels" *Ophthalm Res* 1995; 27: 48-52.
4. Lam DS, Lai TY, Lee VY. "Efficacy of 1,25 mg versus 2,5 mg intravitreal bevacizumab for diabetic macular edema: six month results of a randomized controlled trial". *Retina* 2009; 29: 292-299
5. Otani T, Yamaguchi Y, Kishi S, "Correlation between visual acuity and foveal microstructural changes in diabetic macular edema", *Retina* 2010, 30: 774-780
6. Raafay S, Lu N, Campochiaro P, "Predictors of functional and anatomical outcomes in patients with diabetic macular edema treated with Ranibizumab", *Ophthalmology* 2015, 122; 1395-1401
7. Alasil T, Keane P, Dustin L and al, "Relationship between optical coherence tomography retinal parameters and visual acuity in diabetic macular edema", *Ophthalmology* 2010, 117: 2379-2386