

Choroidal melanoma suspect. Conservative treatment and evolution. Case report

Zemba Mihail* **, Malciolu Radu Alexandru*

*Department of Ophthalmology, "Dr. Carol Davila" Central Military University Emergency Hospital, Bucharest, Romania

**"Carol Davila" University of Medicine and Pharmacy, Bucharest, Romania

Correspondence to: Radu Alexandru Malciolu, MD,
Department of Ophthalmology, "Dr. Carol Davila" Central Military University Emergency Hospital, Bucharest,
12 Liviu Rebreanu Street, Bucharest, Romania,
Mobile phone: +40740 005695, E-mail: rmalciolu@gmail.com

Accepted: September 16, 2016

Abstract

We present the case of a 42-year-old female who presented to our clinic for phosphenes in the left eye, occurring along with eye movement. A diagnosis of choroidal melanoma suspect was made. Due to the patient's profile, young, active woman, surgeon, and the limited therapeutic options in Romania, a conservative treatment and brachytherapy were chosen, which were successfully performed abroad. The patient has been followed-up, so far, for five years after the procedure, with spectacular results.

Keywords: choroidal melanoma, brachytherapy, radiation therapy, radiation retinopathy

Introduction

Choroidal melanoma is the most common primary malignancy of the eye. Historically, enucleation used to be the treatment of choice. However, due to the significant negative impact on the patient and the controversial removal of an eye still capable of useful vision, new treatment options have emerged.

Plaque radiotherapy is one of them. Developed in the 1930s, it consists of attaching a radioactive plaque to the outer sclera, for a mean period of 3 to 7 days, beneath the tumor, which emits tumoricidal radiation. The goal of the treatment is the delivery of a curative dose to the tumor, while minimally damaging the normal ocular structures. The two main radionuclides used are Iodine 125 and Palladium 103, in North America, and Ruthenium 106, in Europe. Radiation therapy gained popularity in the 1990s, once the COMS study (the Collaborative Ocular Melanoma Study) demonstrated the

relative equivalence between Iodine plaque radiation therapy and enucleation, for small and medium sized tumors [3,4,7,8].

Currently, the American Brachytherapy Society guidelines recommended radiation therapy for most uveal melanomas, including iris, ciliary body, choroidal and juxtapapillary tumors, as long as their thickness was less than 5 mm, not invading extrasclerally and the eye was not painfully blind. In these cases, enucleation could be taken into account, but the phenomenon of microscopic metastasis during surgery had to be remembered. Observation was only recommended for small (less than 2 mm thick) tumors, typically for no more than 6 months, so that the documented growth could occur, while the patient was counseled regarding the risks of postponing the treatment [1].

Evolution was favorable, with most of the treated eyes showing a stable or regressed tumor and variable but useful visual acuities. The side effects included radiation dermatitis (rare when using Ruthenium), keratitis, uveitis,

secondary cataract, strabismus, but the most frequent (up to 42% at 5 years) was radiation retinopathy, similar to diabetic retinopathy, first non proliferative then proliferative. Its incidence was between one month and 15 years post radiation, peaking at 6 months - 3 years, especially in macular and juxtapapillary locations, and its treatment consisted of intravitreal injections of either anti-VEGFs or steroids and laser photocoagulation. Therefore, patients who undergo radiation therapy must be carefully followed-up for long periods of time, both locally, in order to assess the tumor status and the side effects, and generally, in search for dissemination [10].

Case report

We present the case of a young, active woman, who presented to our clinic, complaining of phosphenes in the left eye, occurring with eye movement. The patient denied having suffered any trauma was under no treatment and had insignificant previous personal or familial medical history.

Upon the ophthalmic examination, the BCVA LE & RE had the following characteristics: 1 nc, normal IOP and no anterior segment pathological findings. The fundus examination of the RE was normal, however, the LE fundus exam revealed a poorly defined, juxtapapillary, nasal superior, brown pigmented lesion, surrounded by retinal atrophic areas, with a diameter of approx. 1.5 disc areas (Fig. 1).

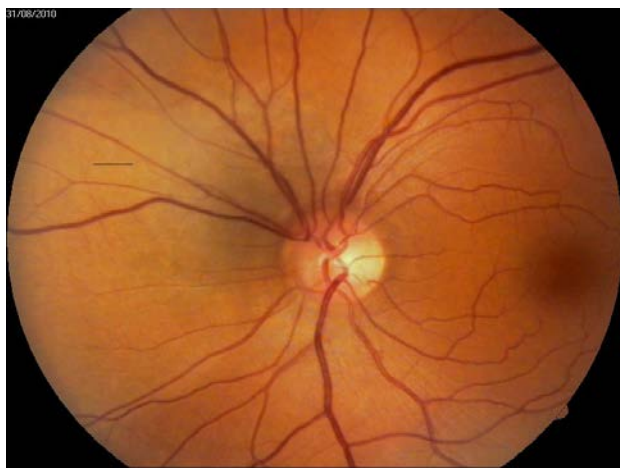


Fig. 1 LE fundus aspect

Firstly, a B-scan ultrasonography was performed, which revealed an elevated, solid biconvex lesion, of approximately 3 mm thick, hyperechogenic, but hypo-reflective towards its base, precisely defined, juxtapapillary located (Fig. 2).

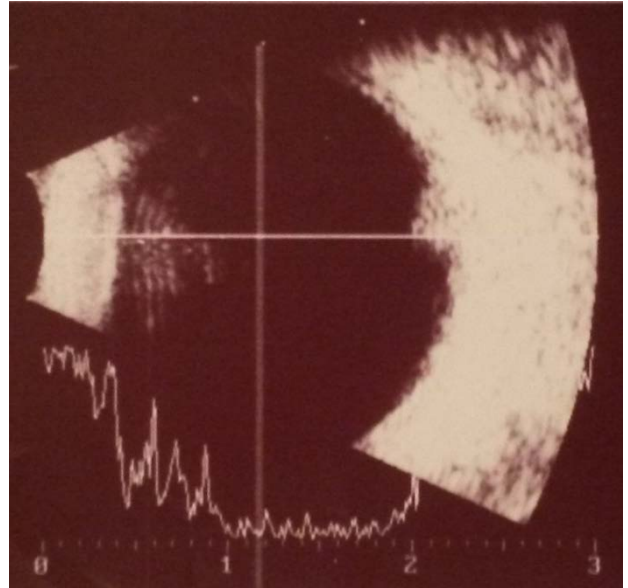


Fig. 2 The elevated lesion on B scan

The OCT revealed a normal, elevated retina and a normal architecture macula (Fig. 3).

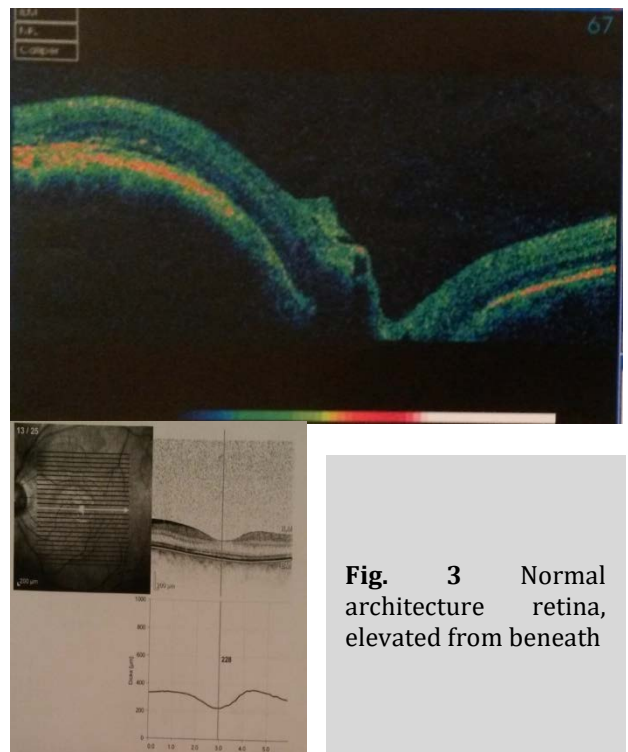


Fig. 3 Normal architecture retina, elevated from beneath

Fluorescein angiography showed a typical hypofluorescent lesion in the early stages, with a diffuse leakage in the extracellular space of the tumor afterwards, and staining during the late frames (**Fig. 4**).

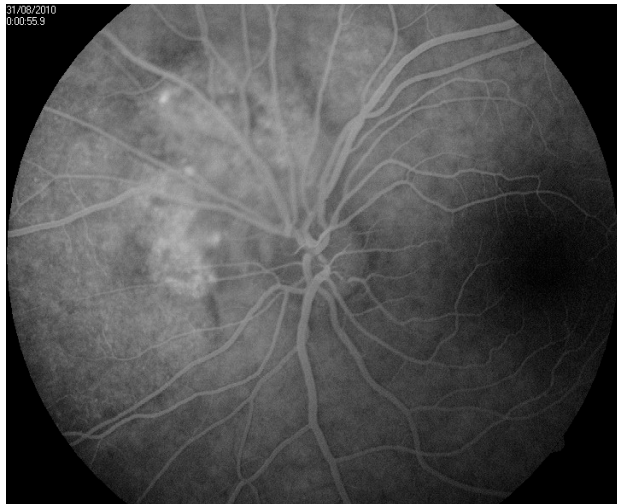

Fig. 4 Diffuse leakage

The general investigations consisted of a full blood count, liver enzymes, abdominal, and especially liver ultrasound and chest X-ray. All the results were within normal limits.

Considering the clinical aspect and investigations, the diagnosis of LE was choroidal melanoma suspect. In order to confirm the suspicion, a biopsy had to be theoretically performed. However, retrospective studies, made on enucleated eyes, have proven that the choroidal melanoma diagnosis could be clinically made with an accuracy of 99.5%; therefore, biopsy was not regarded as necessary for the diagnosis [2].

As for the differential diagnosis, a benign lesion, such as a choroidal nevus, an optic disc melanocytoma, or a metastatic tumor was first taken into account. However, the appearance, especially its thickness of more than 2 mm, location, and investigations guided our diagnosis.

Given the diagnosis and the patient's profile (surgeon), observation was not considered an option, since hematogenous

dissemination eventually occurs in 75% of the patients, usually to the liver, and, once the tumor metastasizes, the survival is estimated at around 7 months. Also, mortality due to uveal melanoma is around 31% at 5 years, and increasing with time [5,11,12].

Unfortunately, in Romania, most of these cases only have one therapeutic solution – enucleation. It is an aggressive treatment, yet a simple solution. However, there have been no comparative data so far between untreated patients and enucleation, and given the Zimmerman-McLean hypothesis on micrometastases, more data is needed for the efficacy of enucleation [13,15].

In our opinion, the best solution for this case was radiation therapy, which, unfortunately, is not available in Romania. Therefore, the patient was sent to an ocular oncology clinic abroad. The patient was admitted, she received a whole body PET-CT, which was normal, and radiation therapy was started immediately, using Ruthenium 106 (Eckert & Ziegler BEBIG).

A beta-radioactive plaque was attached to the outer sclera, juxtapapillary, nasally and superiorly, and was held in place for 7 days. The tumoricidal dose of the Ruthenium plaque, of 60 Gy, was achieved 3 mm away, and at 5mm, it dropped to 10%, making it a good option for sparing normal ocular structures. Also, the plaque was covered in pure silver on its posterior face, thus minimizing the extraocular radiation damage.

The patient had a good evolution, with no immediate side effects. At 3 months, the lesion was stable, with subtle surface pigment changes, the LE BCVA was still 1 nc, but the first side effects appeared – occlusion of both superior and inferior nasal arteries (**Fig. 5**). Humphrey visual fields procedure was performed, and a small temporal scotoma was revealed (**Fig. 6**). However, the patient was content with the evolution.

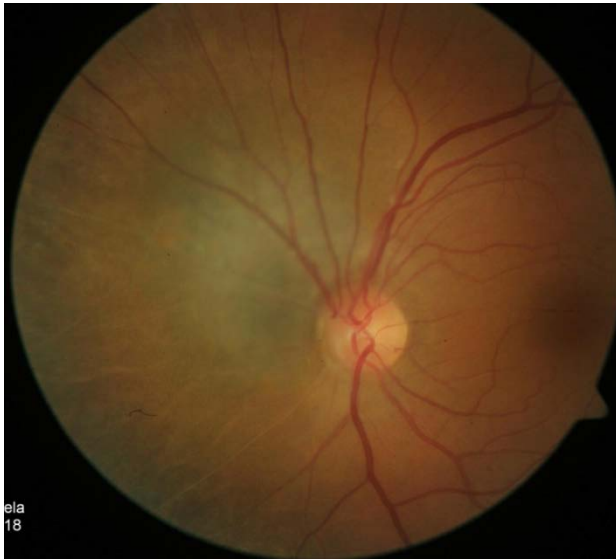

Fig. 5 Nasal ghost vessels

diagnosis of LE was added: radiation retinopathy, which was expected due to the juxtapapillary tumor location.

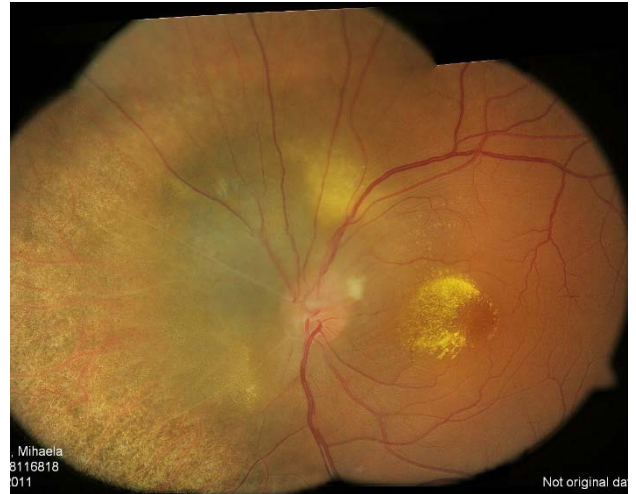

Fig. 7 Radiation retinopathy, perilesional retinal atrophy

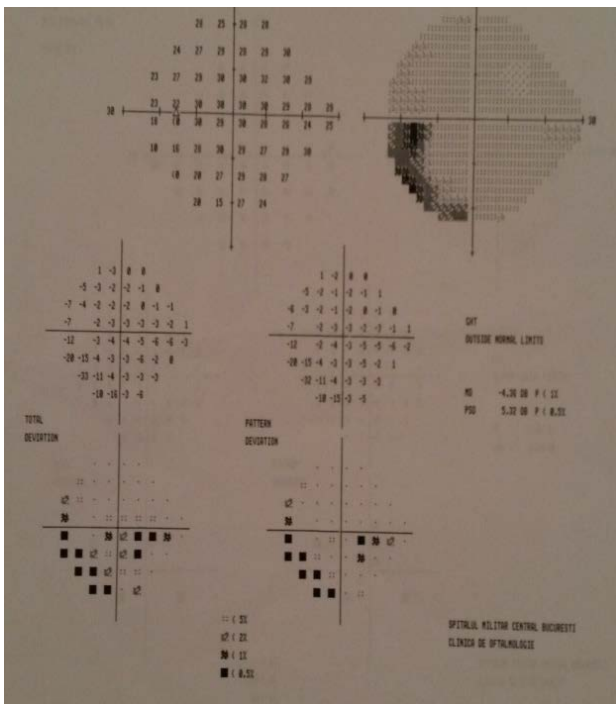


Fig. 6 Functional impact

At 6 months, the patient complained of gradual visual loss in the LE. BCVA dropped to 0.4 nc, and the fundus revealed significant macular edema, macular hard exudates, one peripapillary cotton wool spot and edema on the superior temporal arcade, perilesional retinal atrophy and choroidal folds (Fig. 7). The

The patient received one 0.1 ml intravitreal injection of Triamcinolone acetonide, unfortunately with little effect, one month later, the BCVA being 0.5 nc, with persistent macular edema. Therefore, 0.05 ml intravitreal Bevacizumab was injected and good results followed: BCVA returned to 1 nc and macular edema and exudates gradually resolved over the next 3 months (Fig. 8). Micropulse laser treatment is another viable option in these cases, but not as widely available [6,9,14].

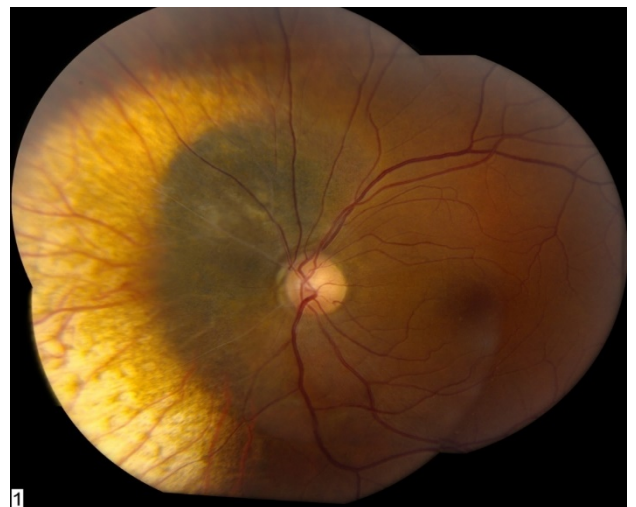

Fig. 8 Resolution of radiation retinopathy

The patient has been followed closely afterwards, for 5 years, having a stable BCVA of 1 nc, and no retinal changes other than the perilesional atrophy due to plaque radiation (**Fig. 9,10**), a normal looking macula (**Fig. 11**), and no other ocular side effects. The tumor is currently less than 2 mm thick (**Fig. 12**), has the same diameter and aspect, and it is surrounded by atrophic retina. The patient had yearly general lab and liver enzyme tests, liver ultrasound, and repeated whole body PET-CTs, with no abnormal findings. She will also be followed closely over the next years, hopefully with a good prognosis. She has a completely normal, active lifestyle and successfully works as a surgeon, which, in our opinion, is a great success.

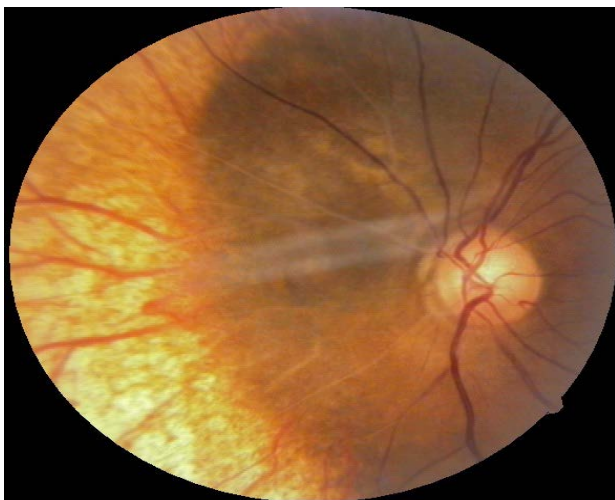

Fig. 9 Clinical aspect

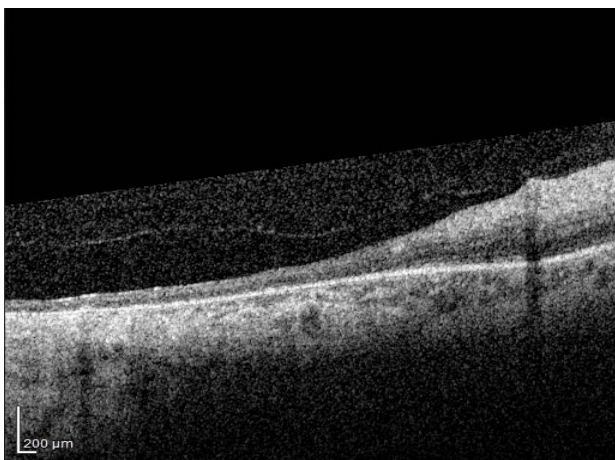


Fig. 10 OCT – retinal atrophy

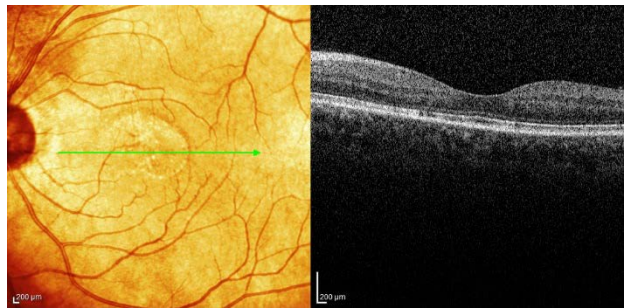


Fig. 11 OCT – normal architecture macula

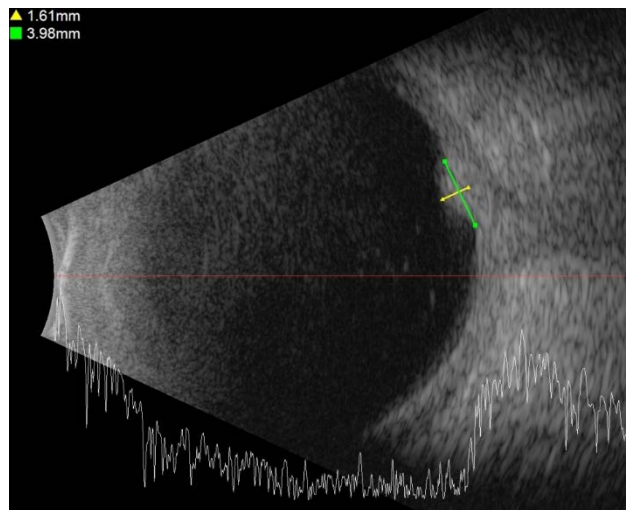


Fig. 12 B scan aspect

Unfortunately, not all the patients with ocular oncologic pathology benefit from the same conservative treatment, and most of them cannot afford the price of such an option abroad, but we are looking forward to treating these patients here, in the near future.

References

1. American Brachytherapy Society - Ophthalmic Oncology Task Force. The American Brachytherapy Society consensus guidelines for plaque brachytherapy of uveal melanoma and retinoblastoma. *Brachytherapy*. 2014; 13:1-14.
2. Accuracy of Diagnosis of Choroidal Melanomas in the Collaborative Ocular Melanoma Study COMS Report No. 1. *Arch Ophthalmol*. 1990; 108(9):1268-1273. doi:10.1001/archophth.1990.01070110084030.
3. Bell DJ, Wilson MW. Choroidal Melanoma: Natural History and Management Options. *Cancer Control*. 2004; 11(5).

4. Tarlan B, Kiratli H. Current Treatment of Choroidal Melanoma. *Expert Rev Ophthalmol.* 2012; 7(2):189-195.
5. Collaborative Ocular Melanoma Study Group. Assessment of metastatic disease status at death in 435 patients with large choroidal melanoma in the Collaborative Ocular Melanoma Study (COMS): COMS report No. 15. *Arch Ophthalmol.* 2001; 119:670-676.
6. Finger PT, Chin KJ, Semenova EA. Intravitreal anti-VEGF therapy for macular radiation retinopathy: a 10-year study. *Eur J Ophthalmol.* 2015. doi:10.5301/ejo.5000670.
7. Finger PT. Radiation therapy for choroidal melanoma. *Surv Ophthalmol.* 1997; 42:215-232.
8. Finger PT. Radiation therapy for orbital tumors: concepts, current use, and ophthalmic radiation side effects. *Surv Ophthalmol.* 2009; 54:545-568.
9. Finger PT. Radiation Retinopathy: Prevention and Suppression. Anti-VEGF agents are making a key difference. *Retinal Physician.* 10/01/2015.
10. Gündüz K, Shields CL, Shields JA, Cater J, Freire JE et al. Radiation retinopathy following plaque radiotherapy for posterior uveal melanoma. *Arch Ophthalmol.* 1999; 117:609-614.
11. Kath R, Hayungs J, Bornfeld N et al. Prognosis and treatment of disseminated uveal melanoma. *Cancer.* 1993; 72:2219-2223.
12. Kujala E, Makitie T, Kivelä T. Very long-term prognosis of patients with malignant uveal melanoma. *Invest Ophthalmol Vis Sci.* 2003; 44:4651-4659.
13. Singh AD, Rennie IG, Kivela T, Seregard S, Grossniklaus H. The Zimmerman-McLean-Foster hypothesis: 25 years later. *The British Journal of Ophthalmology.* 2004; 88(7):962-967. doi:10.1136/bjo.2003.029058.
14. Wong M, Halpern RL. Micropulse Laser Treatment for Macular Edema Resulting From Radiation Retinopathy. *Retina Today.* 01-02.2016.
15. Zimmerman LE, McLean IW, Foster WD. Does enucleation of the eye containing a malignant melanoma prevent or accelerate the dissemination of tumour cells. *Br J Ophthalmol.* 1978; 62:420-5.